ELSEVIER

Ocular Dominance in Anterior Visual Cortex in a Child Demonstrated by the Use of fMRI

Atsushi Miki, MD, PhD, Grant T. Liu, MD, Douglas W. Fletcher, PhD, Jill V. Hunter, MD and John C. Haselgrove, PhD

Negative signal changes in the visual cortex have been observed during visual stimulation when performing functional magnetic resonance imaging (fMRI) in children. This report investigated whether the ocular dominance, which has been demonstrated in the contralateral anterior visual cortex in adults, could be observed in a child by the use of fMRI. A 5-year-old child was studied using fMRI at 1.5 T during alternating monocular visual stimulation under sedation with morphine and pentobarbital. The functional images were motion corrected, and statistical parametric maps were made by contrasting the left or right eye stimulation conditions vs the right or left eye stimulation conditions, respectively, at each voxel. Areas with negative signal changes were found on the left anterior visual cortex during monocular visual stimulation of the right eye and vice versa. There was no area with negative or positive signal change on the ipsilateral visual cortex to the stimulated eye and no area with positive signal change on the contralateral visual cortex. Contralateral ocular dominance of anterior visual cortex similar to that of adults was demonstrated in this child with a negative correlation with the visual stimulus. This finding suggests that peripheral visual fields are represented in the anterior visual cortex of 5-year-old children. **© 2001 by Elsevier Science Inc. All rights reserved.**

Miki A, Liu GT, Fletcher DW, Hunter JV, Haselgrove JC. Ocular dominance in anterior visual cortex in child demonstrated by the use of fMRI. Pediatr Neurol 2001;24:232-234.

Introduction

Functional magnetic resonance imaging (fMRI) of the brain has been performed in infants and children, and a signal decrease of the visual cortex during visual stimulation, contrary to signal increase demonstrated in fMRI of adults (blood oxygenation level-dependent contrast), has been demonstrated [1-7]. Because this phenomenon was first found in children who were under sedation, subsequent studies were performed to clarify whether this finding resulted from the effect of sedative drugs or the young age of the subjects [3]. Sedated adults demonstrated signal increase during visual stimulation, and therefore the signal decrease observed in children was considered to be age dependent [3]. A near-infrared spectroscopy study in awake infants also demonstrated that changes in the concentration of deoxyhemoglobin of the visual cortex during visual stimulation in children were positive whereas the changes in adults were negative, suggesting increased cerebral oxygen utilization in children [8].

Ocular dominance, because of the difference in connections from nasal and temporal retinae and visual fields, has been demonstrated in contralateral anterior visual cortex in fMRI by comparing the monocular visual activation of normal human subjects [9]. In this study a 5-year-old child under sedation was studied to investigate whether such ocular dominance could be observed in a young, sedated child as negative signal changes.

Case Report

A male patient 5 years of age with a venous sinus thrombosis that did not affect his vision is presented. He had a normal neuro-ophthalmic examination except for esotropia and displayed normal visual acuities and normal confrontational visual fields. The patient's parent signed a consent form approved by the Institutional Review Board of the Children's Hospital of Philadelphia. The clinical MRI examination for the sinus thrombosis was followed by this fMRI experiment.

The subject was studied under sedation with IV morphine sulfate (2 mg) and pentobarbital (4 mg/kg) while lying supine in a Siemens Vision 1.5 T whole body scanner. Light-proof binocular goggles (S10VSB, Grass instruments. Quincy, MA) were placed over the patient's eyes, and

From the Children's Hospital of Philadelphia Functional MRI Research Unit and the University of Pennsylvania School of Medicine, Philadelphia, Pennsylvania.

Communications should be addressed to:
Dr. Miki; Division of Neuro-ophthalmology; Department of Neurology; Hospital of the University of Pennsylvania; 3400 Spruce Street, Philadelphia, PA 19104.
Received July 5, 2000; accepted November 13, 2000.

© 2001 by Elsevier Science Inc. All rights reserved.
PII S0887-8994(00)00260-5 • 0887-8994/01/$—see front matter

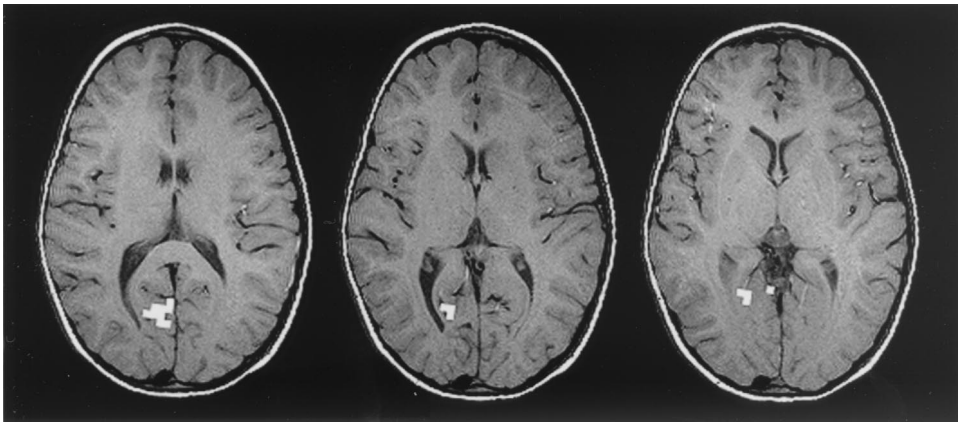

Figure 1. The activation map superimposed on the corresponding T_1-weighted images. Activated areas obtained by contrasting the condition of left eye stimulation vs the condition of right eye stimulation. The right side of the brain is on the left. (T_1-weighted images: TR = 600 ms, TE = 20 ms.)

his head was insulated firmly with foam padding within the quadrature head coil to discourage motion. For the functional study, 16 slices parallel to the calcarine fissure at 5-mm spacings were imaged with a field of view (FOV) equaling 240 mm. Each functional study was preceded by a T_1-weighted spin echo sequence (TR/TE = 600/20 ms, matrix 256 × 256, slice thickness = 3 mm, interslice space = 2 mm). Functional images were acquired in identical planes using a T_2-weighted (TR = 1.68 ms [interscan interval = 3 seconds], TE = 64 ms, 90-degree flip angle) echo-planar image (EPI) sequence with a 64 × 64 matrix, FOV 240 mm, and 5-mm thick slices. The visual stimulus was provided by the light-emitting diode goggles through the patient's eyelids. The goggles flashed at the rate of 8 Hz. The left-eye stimulation condition alternated with right-eye stimulation condition. Each condition lasted for 30 seconds (10 scans). Each cycle of the alternation was repeated six times.

Data analysis was performed on UNIX workstations. IDL (Interactive Data Language, CO) and SPM96 (Wellcome Department of Cognitive Neurology, London, UK) were used for data analysis. The first five EPI images were discarded to ensure that only images acquired when the system had reached a steady state were used for analysis. The EPI images were realigned to the first scan. The intensity of successive image sets was normalized to compensate for any slight drift of signal. Statistical parametric maps were constructed using Student's *t* statistic. The activation threshold was set at the *P* value of 0.05 after the Bonferroni correction. Activated voxels were identified by their negative correlation with the stimulus. The activation map was superimposed on the corresponding T_1-weighted images.

On the anatomic T_1-weighted images, there was no structural abnormality of the visual pathways. The patient was studied successfully without significant head motion during the acquisition of functional images.

The activation areas detected by the negative signal changes were found in the right anterior visual cortex for the left eye vs right eye contrast, and in the left anterior visual cortex for the right eye vs left eye contrast (Figs 1 and 2). The areas extended laterally from the midline and were just posterior to the parieto-occipital sulcus. Therefore most of the activated area presumably corresponds to the primary visual cortex. Areas with negative signal changes on the ipsilateral visual cortex to the stimulated eye were not found. Also, there was no area with significant positive signal changes for each contrast.

Discussion

Previous fMRI reports suggest that visual activation can be elicited in sleeping infants and children [1-7] even when a visual stimulus through the eyelids is used [1-3, 5-7]. Visual stimulation in infants and children induces signal decrease in the visual cortex as opposed to signal increase in adults. The mechanism for this phenomenon is unknown, but a different coupling of regional cerebral blood flow response and oxygen metabolism during neural

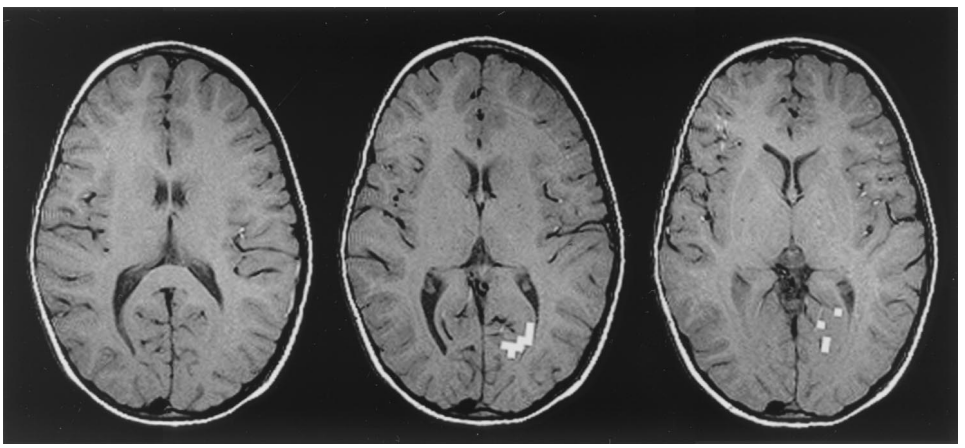

Figure 2. The activation map superimposed on the corresponding T_1-weighted images. Activated areas obtained by contrasting the condition of right-eye stimulation vs the condition of left-eye stimulation. The right side of the brain is on the left. (T_1-weighted images: TR = 600 ms, TE = 20 ms.)

activity in young children from that in adults has been suggested. This mechanism may result from increased oxygen consumption during the development of brain. Although sedative drugs may reduce the amount of signal increase, probably depending on the drug used, sedated adults manifest signal increase during visual stimulation [3]. In addition, unsedated infants revealed negative signal changes [4]. Therefore the signal decrease is thought to depend mainly on the subject's age.

Although previous reports in children consistently have demonstrated signal decrease in response to visual stimulation, there may be differences in the way different sedative drugs affect fMRI signal changes. Therefore the signal decrease may be or may not be detectable even in children at the same age depending on the type of sedative administered. In previous reports, halothane [4] was used for general anesthesia, and chloral hydrate [1,3-6] and pentobarbital [2,4,7] have been used for sedation. These drugs may provoke various levels of effects on cerebral blood flow, and such effects remain to be studied. Pentobarbital may have suppressed the cerebral blood flow response and strengthened negative signal change in our patient [4].

The activated area by binocular full-field visual stimulation, detected by the negative correlation with the visual stimulus, is located more anteriorly within the visual cortex in the children as compared with the adults, especially in younger infants [1-4,6,7]. The area appears to lie on the primary visual cortex, but activation in the posterior visual cortex, which represents the fovea, is often lacking. A most-likely explanation for the absence of activation is that there may be a canceling out of cerebral blood flow and oxygen consumption in this area [3]. This phenomenon has been observed in children in whom visual function is found to be normal. An alternative explanation is that this is because of a reorganization of visual cortex during development [3].

The activated area by one eye but not by the other appears to correspond well to the cortical area associated with the monocular temporal crescent, given the anterior location of the area. In addition, because there are considerable nasotemporal asymmetries in the retinal ganglion cells and visual perception [10-12], some of the area may have resulted from the difference in the sensitivity between nasal and temporal visual fields. Most activated voxels are very close to the cuneal point [13]; we consider most areas to be in the primary visual cortex. Also, we used a simple flash stimulus, which usually produces activation around the calcarine fissure, especially in V1. Therefore it is more likely that the stimulus has induced activation of earlier visual areas rather than that of higher visual cortex. However, it is possible that the area includes extrastriate cortex.

The activated area detected by negative signal changes in this child resembles those detected by positive signal changes in fMRI of adults [9]. Accordingly, it is suggested that peripheral visual fields are represented in anterior visual cortex in 5-year-old children, just like adults. Because it is difficult to perform formal visual-field testing and accurate clinicopathologic correlation in infants and children, the fMRI technique may be useful in further challenging studies investigating retinotopic organization in the visual cortex.

This work was supported by Prevent Blindness America, Post-Doctoral Research Fellowship, PD98017 (A.M.).

References

[1] **Born** P, Rostrup E, Leth H, Peitersen B, Lou HC. Change of visually induced cortical activation patterns during development. Lancet 1996;347:543.

[2] **Yamada** H, Sadato N, Konishi Y, et al. A rapid brain metabolic change in infants detected by fMRI. NeuroReport 1997;8:3775-8.

[3] **Born** P, Leth H, Miranda MJ, et al. Visual activation in infants and young children studied by functional magnetic resonance imaging. Pediatr Res 1998;44:578-83.

[4] **Martin** E, Joeri P, Loenneker T, et al. Visual processing in infants and children studied using functional MRI. Pediatr Res 1999;46: 135-40.

[5] **Liu** GT, Hunter J, Miki A, Fletcher DW, Brown L, Haselgrove JC. Functional MRI in children with congenital structural abnormalities of the occipital cortex. Neuropediatrics 2000;31:13-5.

[6] **Born** P, Miranda MJ, Rostrup E, et al. Functional magnetic resonance imaging of the normal and abnormal visual system in early life. Neuropediatrics 2000;31:24-32.

[7] **Morita** T, Kochiyama T, Yamada H, et al. Difference in the metabolic response to photic stimulation of the lateral geniculate nucleus and the primary visual cortex of infants: A fMRI study. Neurosci Res 2000;38:63-70.

[8] **Meek** JH, Firbank M, Elwell CE, Atkinson J, Braddick O, Wyatt JS. Regional hemodynamic responses to visual stimulation in awake infants. Pediatr Res 1998;43:840-3.

[9] **Miki** A, Liu GT, Raz J, et al. Contralateral monocular dominance in anterior visual cortex confirmed by functional magnetic resonance imaging. Am J Ophthalmol 2000;130:821-4

[10] **Curcio** C, Sloan KR, Kalina RE, Hendrickson AE. Human photoreceptor topography. J Comp Neurol 1990;300:497-523.

[11] **Curcio** C, Allen KA. Topography of ganglion cells in human retina. J Comp Neurol 1990;300:5-25.

[12] **Fahle** M, Schmid M. Naso-temporal asymmetry of visual perception and of the visual cortex. Vision Res 1988;28:293-300.

[13] **Rademacher** J, Caviness VS, Steinmetz H, Galaburda AM. Topographical variation of the human primary cortices: Implications for neuroimaging, brain mapping, and neurobiology. Cereb Cortex 1993;3: 313-29